

Recognizing the signs of retinoblastoma

Juliette Carter explains the importance of recognizing the signs of retinal cancer in children as early as possible to avoid unnecessarily aggressive treatment

Retinoblastoma is a malignancy which develops in the retina of children usually under the age of 5 years. It is most commonly detected by parents (Wallach et al, 2006) who seek advice in general practice or from an optician. Unfortunately, many patients face a delay in diagnosis and treatment owing to a lack of awareness of the significance of the signs described by parents or observed by primary health professionals (Goddard et al, 1999). The common signs of retinoblastoma will be highlighted in this article and the investigations and management of a patient in general practice will be discussed.

Epidemiology

Retinoblastoma is a rare cancer but is the most common primary ocular tumour in children (Butros et al, 2002, Wallach et al, 2006). It accounts for approximately 1 in 20 000 live births and on average 40 cases are diagnosed in the UK each year (MacCarthy et al, 2009). One or more tumours may be present in one eye (unilateral retinoblastoma) or both eyes (bilateral retinoblastoma). Tumours grow in the developing retina, the light-sensitive lining of the eye. Some children are born with retinoblastoma tumours; for others, retinoblastoma can develop any time until the age of approximately 5 years, when the retina has finished developing.

There are two forms of retinoblastoma: sporadic and heritable. A child can be the first in his/her family to develop the heritable con-

dition but that person will then have a 50% chance of passing the genetic mutation onto his/her future children. When a child is diagnosed, the parents' eyes will be checked for a regressed tumour and genetic testing can be done to detect where the gene mutation first occurred.

Patients with bilateral disease or multifocal tumours in one eye have heritable retinoblastoma. This accounts for approximately 44% of all retinoblastoma patients (Draper et al, 1992). Those with unilateral retinoblastoma have the sporadic form. Although retinoblastoma is highly treatable, the severity and impact of treatment will depend on the size of the tumour(s) and their location at the time of diagnosis.

Signs and symptoms

The most common sign of retinoblastoma is leukocoria, a white pupillary reflection (*Figure 1*). Strabismus, a squint, is also a common indicator. Other signs which may be picked up by a parent, relative, or primary health professional may be poor or decreased vision, or pseudo-orbital cellulitis; and a known family history of retinoblastoma (Goddard et al, 1999; Butros et al, 2002; Abramson et al, 2003; Lin, 2003; Wallach et al, 2006). A few extremely rare signs which are still worth noting are heterochromia (a difference in iris colour between the eyes), secondary glaucoma and proptosis. Retinoblastoma may occasionally cause some localized pain but in general, apart from the often intermittent signs mentioned above, children seem well, happy and active, making it more difficult to realize the child has a life-threatening disease.

Presentation

Children present to general practice with suspected retinoblastoma at different ages depending on the form the child may have. A child with the heritable form is usually diagnosed within the first year of life, with the average age at diagnosis being 9 months. Cases of sporadic retinoblastoma usually present much later and the average age at diagnosis is 24 months (Wallach et al, 2006).



Figure 1. Boy with white reflex in his eye

Juliette Carter is support worker and information officer, Childhood Eye Cancer Trust, The Royal London Hospital, Whitechapel Road, London E1 1BB

Submitted for peer review 6 April 2009; accepted for publication 7 April 2009

Key words: Retinoblastoma, eye cancer, childhood cancer, squint, white eye reflex

Table 1. Signs of retinoblastoma

Problem	Symptoms and implications	Description by family	Investigation
Leukocoria	White reflection in the pupil. Intermittently present or seen in flash photographs	'Flashes like a cat's eye' 'Looks like a jelly' 'Sometimes I can see into the back of the eye'	Red reflex test
Strabismus	A squint	'Lazy eye' An eye is 'turned in' 'One eye moves independently'	Red reflex test
Poor vision	A child with retinoblastoma may have always had poor vision or it may have deteriorated	'Their eyes won't fix or follow' 'One eye moves independently'	Red reflex test
Red or inflamed eye	The areas around the eye are red or inflamed—it may look like orbital cellulitis		Red reflex test
Family history of retinoblastoma	There is a 50% chance a parent will pass the heritable form of retinoblastoma onto the child. There is a small chance a child of someone with the sporadic form will be affected	Not every adult who had retinoblastoma as a child is aware of the risks to his/her children—so the children need to be screened. Some adults were never told by their parents what condition they had as a baby	Red reflex test and referral to a retinoblastoma centre

Parents often find it difficult to describe the abnormality they have seen in their child and may have no idea what it could be. Leukocoria may only be visible intermittently. It occurs when the pupils are dilated in low artificial light. It can also be caught in flash photography as an absence of red eye. One eye may show up as normal with red eye but the other may look white, yellow or in some cases black. It is possible that both pupils may look unusual in a photograph. Some parents take a photograph with them when they see a primary health professional. In a small number of cases the tumour has grown so large that leukocoria, sometimes a red or yellow mass or a change in iris colour is visible most of the time (*Table 1*).

It is important to consider when examining children with any of these symptoms that consulting rooms are generally well-lit, which may prevent a primary health professional from noticing any of the signs. Many parents whose children have strabismus are reassured that a squint is normal in babies. In truth it is common but it needs to be investigated as a child with retinoblastoma tumours cannot wait the usual 3 months for a squint referral. In this time the tumours may grow rapidly resulting in the need for more aggressive treatment, with the possibility of losing an eye and/or some vision. With any of the symptoms mentioned above, no matter how common the symptoms may appear or how healthy the child looks, the primary health

professional should consider retinoblastoma as a possible cause. A simple red reflex test can be performed to help identify whether there are any unusual areas on the retina. A swift referral to an ophthalmologist to investigate further will ensure that if a child has retinoblastoma, diagnosis and treatment will be necessarily prompt.

Examination

If a child under the age of 5 years presents with any of the possible retinoblastoma symptoms, a red reflex test should be performed, even though retinoblastoma is rare. A red reflex examination is non-invasive and can help when deciding whether the child needs to be referred. The red reflex test needs to be performed by someone who is experienced in doing it as it can sometimes present false negative or false positive results. Someone in a general practice may be trained to do this test but, if not, it can be done at an ophthalmology clinic.

The investigation involves looking into the back of the child's eye at the retina. It is performed using a halogen ophthalmoscope and should be done in a dark room. The professional performing the red reflex test will need to look at the whole of the retina, right to the peripheries. It can be difficult to do this test on babies and young children as they will not be able to cooperate; however, they can be encouraged to look at a toy behind the professional while he/she is working.

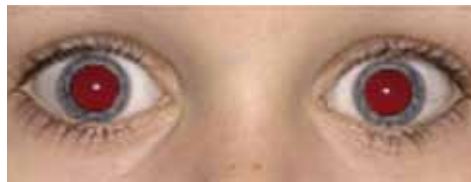

Figure 2. Eyes with normal red reflex

Ophthalmoscopy

A halogen ophthalmoscope can show some of the symptoms of retinoblastoma. *Figure 2* shows a normal presence of the red reflex. This is caused by the flash from the camera bouncing off the retinas at the back of the eye. Some people refer to this as 'red eye'. *Figure 3* shows an absence of the red reflex in the child's left eye. It may be absent from one or both eyes. This is a sign of serious eye disease such as retinoblastoma, and will need investigation.

Figure 4 shows a red reflex which is the wrong colour and brightness. This may be present in one or both eyes. It suggests serious eye disease such as retinoblastoma and needs investigation. *Figure 5* shows the red reflex is reduced in the left eye and the corneal reflex is not central. This is a squint which requires prompt investigation to exclude serious underlying disease.

When specialist consultants in retinoblastoma diagnose children, they take a photo of the retina on a RetCam. *Figure 6* shows a healthy retina and *Figure 7* shows a retinoblastoma tumour. Tumours will differ in each individual child. They may be different in size, shape, position and quantity.

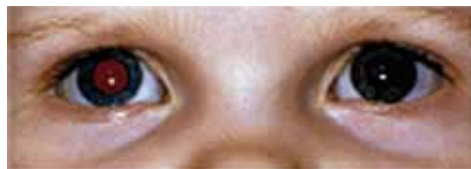

Figure 3. Red reflex absent in left eye

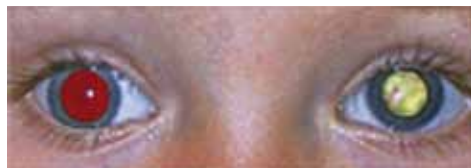

Figure 4. White reflex showing leukocoria

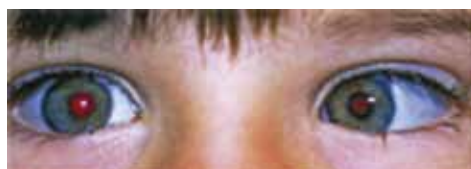

Figure 5. Eyes showing strabismus (squint)

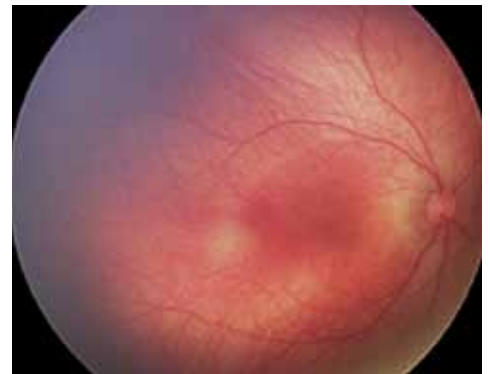


Figure 6. Normal retina

Referral

If retinoblastoma is suspected, or there are concerns but a red reflex examination cannot be done in general practice, refer the child to a local ophthalmologist. The referral should be made within a few days. Health professionals should not delay, as retinoblastoma tumours grow very rapidly and put the child's life at risk.

If retinoblastoma is strongly suspected, parents can be prepared, even though a full diagnosis cannot be made until the child is seen under anaesthetic by a specialist ophthalmologist. An understanding of the treatment of retinoblastoma can enable practice nurses to help prepare a child and his/her family if necessary for the treatment ahead.

If a patient is referred to an ophthalmologist, it is appropriate to inform the patient about the concerns and suspicions. This can be done by telling a child and his/her parents that a specialist eye examination is taken for many reasons and that it is important to rule out anything serious. Other conditions which may present with leukocoria are cataract, Coats' disease, toxoplasmosis and persistent hyperplastic primary vitreous. It is not necessary to tell the families of all patients that eye cancer is suspected, but some families will

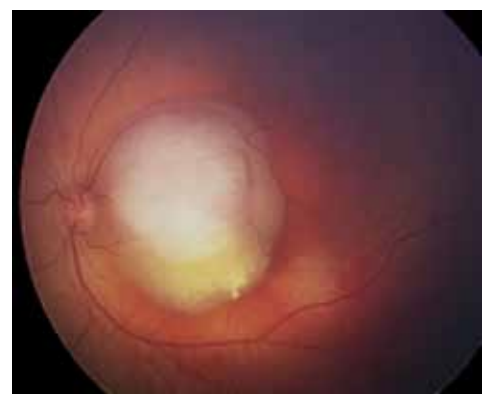

Figure 7. Retinoblastoma tumour

already know about eye cancer as there have been articles in the mass media alerting people to the warning signs. If parents already have such concerns then reassure them that eye cancer is very rare and sometimes the signs and symptoms are indicative of something else less severe. Most importantly inform them that retinoblastoma is treatable and survival rates extremely high. Childhood cancers are different from adult cancers with which they may be more familiar.

Treatment for retinoblastoma

In the treatment of retinoblastoma the first principle is to save the patient's life and then to save his/her vision. Each eye is assessed individually. The type of treatment used will be determined by the size and location of the tumour(s).

For small or relapsed tumours, cryotherapy (freezing) or laser therapy can be used. Chemotherapy is used to treat bigger tumours; this is usually given in six cycles and is likely to be the first option for children with tumours in both eyes.

In cases where the tumour is so large it is in danger of metastasizing or becoming extraocular, enucleation (surgical removal of the eye) is performed. Of 104 children with treatment details diagnosed with unilateral retinoblastoma without family history between 2001–2005, 90 (86.5%) had enucleation according to unpublished data from the National Registry of Childhood Tumours.

They will have an implant inserted during surgery to improve the cosmetic effect and a prosthetic eye will be fitted 6 weeks after surgery. The removed eye will be sent for histology testing and checked to see if tumour cells have invaded any structures within the eye, for example, the choroid (pigmented layer in the eye) and the optic nerve. If this is the case chemotherapy is needed.

Other treatment of retinoblastoma may include second-line chemotherapy, radioactive plaque therapy or radiotherapy. These treatments are only used if the initial treatments mentioned above have not worked, when new tumours develop or if old tumours become active again.

In the past radiotherapy and enucleation were the first-line treatment options before chemotherapy became widely used by specialists to treat retinoblastoma. All children who have been treated for retinoblastoma will have to be regularly checked after treatment for any recurrence.

Conclusions

Retinoblastoma is a rare malignancy of the retina which affects children under the age of 5 years. It can be detected by four main signs, leukocoria, strabismus, poor or decreased vision and red inflamed eye. These signs are most commonly noticed by parents. Leukocoria particularly can be difficult for parents to describe. If a child presents to the practice with any of these signs, a red reflex test should be done and if suspicions remain, it is necessary to refer the child quickly to the local ophthalmology department. Children with strabismus often wait far too long to be seen by an ophthalmologist; this must not be the case if eye cancer is suspected. A delay of a few months often means treatment is unnecessarily aggressive.

Acknowledgments: Figure 1 is reproduced with parental permission, and Figures 6 and 7 with the kind permission of Mr Ashwin Reddy, consultant paediatric ophthalmologist, Barts and the London NHS Trust

Conflict of interest: none

References

- Abramson D, Beaverson K, Sangani P et al (2003) Screening for retinoblastoma: presenting signs as prognosticators of patient and ocular survival. *Pediatrics* 112(6): 1248–55
- Butros L, Abramson D, Dunkel I (2002) Delayed diagnosis of retinoblastoma: analysis of degree, cause and potential consequences. *Pediatrics* 109(3): e45
- Draper G, Sanders B, Brownbill P, Hawkins M (1992) Patterns of risk of hereditary retinoblastoma and applications to genetic counselling. *Br J Cancer* 66(1): 211–9
- Goddard A, Kingston J, Hungerford J (1999) Delay in diagnosis of retinoblastoma: risk factors and treatment outcome. *Br J Ophthalmol* 83(12): 1320–3
- Lin Y (2003) Early recognition of infant malignancy: the five most common infant cancers. *Neonatal Netw* 22(5): 11–9
- MacCarthy A, Birch J, Draper G, Hungerford J et al (2009) Retinoblastoma: treatment and survival in Great Britain 1963 to 2002. *Br J Ophthalmol* 93(1): 38–9
- Wallach M, Balmer A, Munier F et al (2006) Shorter time to diagnosis and improved stage at presentation in Swiss patients with retinoblastoma treated from 1963 to 2004. *Pediatrics* 118(5): e1493–8

Further information

Childhood Eye Cancer Trust

www.chect.org.uk

'See Red' is a poster which explains how to do the red reflex test. For a free copy, telephone 020 7377 5578 or email info@chect.org.uk

Barts and the London NHS Trust

www.bartsandthelondon.nhs.uk/Retinoblastoma_Service/

Birmingham Children's Hospital NHS Foundation Trust

www.bch.org.uk/departments/retinoblastoma.htm

KEY POINTS

- Childhood eye cancer is very treatable if diagnosed early
- Many children need to have an eye removed as a result of delayed diagnosis
- The main signs of retinoblastoma are a white reflection in the pupil, a squint and reduction of vision. One or all symptoms may be present
- The child's retinas should be checked using the red reflex test
- If anything unusual is noticed in the retina then the child needs an urgent referral to an ophthalmologist